



Duckworth & Kent

Ophthalmic Titanium Surgical Instruments

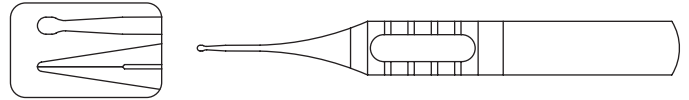
Khaw Glaucoma Instruments

Titanium Instruments

2-502

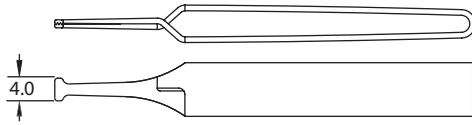
Khaw Transconjunctival Adjustable Suture Control Forceps

- 5.0mm highly polished tying platforms with a flared tip
- For massaging and adjusting intraocular pressure to desired level
- Adjustable Suture Control technique
- Straight shafts
- Standard handle, length 85.0mm



2-686

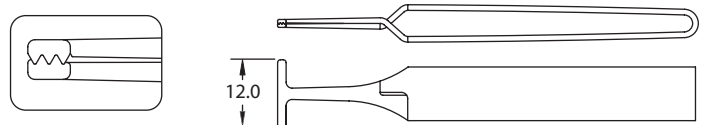
Khaw Small Conjunctival Clamp



- Holds conjunctiva securely
- Holds and protects the conjunctival edge during antimetabolite application
- Particularly during fornix based conjunctival incisions

2-687

Khaw Large Conjunctival Clamp

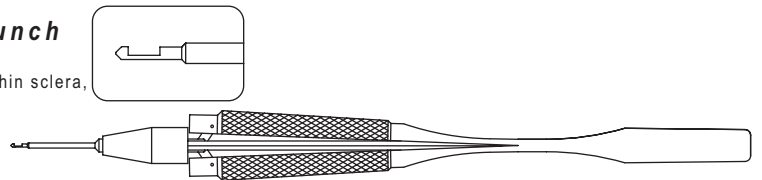


- Single handed action
- Tip width 4.0mm (2-686, small) or 12.0mm (2-687, large)
- Overall length 74.5mm

7-101

Khaw Small Descemet Membrane Punch

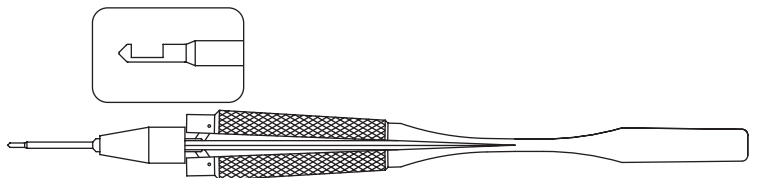
- Designed to punch 0.3mm x 0.5mm
- Particularly suited when small sclerostomy required (e.g. thin sclera, small scleral flap)
- Punch action can be repeated to create larger sclerostomy
- Can be used with a short scleral tunnel incision
- Squeeze action handle activates shaft to punch
- Round squeeze handle, length 131.0mm



7-102

Khaw Descemet Membrane Punch

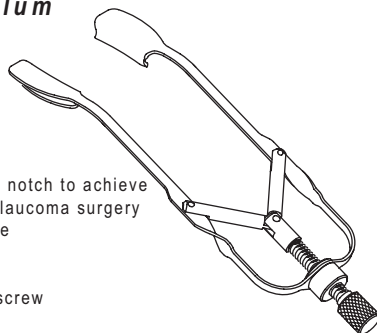
- Designed to punch 0.75mm x 0.5mm
- Can be used with a short scleral tunnel incision
- Squeeze action handle activates shaft to punch
- Round squeeze handle, length 131.0mm



9-576

Khaw Standard Glaucoma Surgery Speculum

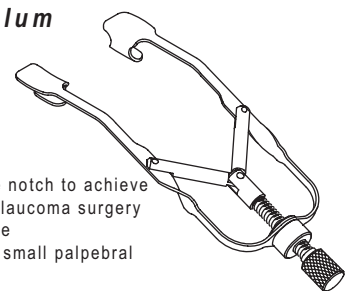
- Central indent and side notch to achieve maximal exposure for glaucoma surgery
- Minimal pressure on eye
- Solid blades
- Angled to rest temporal
- Adjustable with thumb screw



9-576-1

Khaw Small Glaucoma Surgery Speculum

- Central indent and side notch to achieve maximal exposure for glaucoma surgery
- Minimal pressure on eye
- Small size for use with small palpebral apertures and children
- Solid blades
- Angled to rest temporal
- Adjustable with thumb screw



Duckworth & Kent Ltd.

Terence House
7 Marquis Business Centre
Royston Road, Baldock
Herts SG7 6XL England

Tel: +44 (0)1462 893254 Fax: +44 (0)1462 896288
Web: www.duckworth-and-kent.com
Email: info@duckworth-and-kent.com

www.duckworth-and-kent.com



Trabeculectomy – the Moorfields Safe Surgery System

Peng Tee Khaw PhD FRCS FRCOphth FRCP FRCPATH FIBiol FMedSci
Professor of Glaucoma and Ocular Healing
Glaucoma Unit and ORB (Ocular Repair and Regeneration Biology)
Divisions of Glaucoma and Pathology
Institute of Ophthalmology and Moorfields Eye Hospital
11-43 Bath Street, London EC1V 9EL email: p.khaw@ucl.ac.uk

Introduction

This chapter addresses the current techniques used in glaucoma filtration surgery, in particular a guarded sclerostomy procedure best known as trabeculectomy. The decision to perform glaucoma surgery represents a key point in the long-term management of the patient's disease, and should only be made after detailed consultation with the patient. The timing of surgery and selection of appropriate procedure need careful consideration and consultation. It is important to remember that the pre-operative and post-operative management are critical determinants of the outcome of glaucoma surgery.

The field of glaucoma surgery is undergoing a period of revolution with many new approaches to the traditional methods of surgery. Like all surgery, it is essential that surgeons have a sound understanding of the principles involved in the modern range of surgical procedures, and keep up to date with new procedures so that technique can be varied depending on the surgical circumstances. An example of a new techniques that have revolutionised glaucoma surgery and are still changing is the use of adjuvant therapies to modify post-operative wound healing. The identification of relative risk factors for failure of glaucoma surgery enables the surgeon to vary the adjuvant therapy as appropriate while minimising the risk.

Glaucoma filtration surgery was previously performed when patients had uncontrolled intraocular pressures on maximally tolerated medical treatment, or after failed laser trabeculoplasty. The main reasons for delaying surgery were the risk of post-operative complications associated with standard trabeculectomy procedures and high failure rates for operations in certain sub-groups of glaucoma patients. Technical modifications to the trabeculectomy procedure including adjustable stitch techniques combined with the use and techniques of application of these powerful antimetabolites now enable the surgeon to have much greater control of both the operation and post-operative scarring. The identification of patients at risk of developing post-operative hypotony and the continuing development of surgical measures to reduce this risk have been important advances. The risks of surgery in each individual patient should be balanced against the projected visual loss which will occur from glaucomatous damage if the intraocular pressures are not adequately controlled. The techniques described in the following sections are continuously changing with the aim of making glaucoma surgery as safe and successful as possible.

Anaesthesia

See handout on the internet www:/ucl.ac.uk/ioo/research/khawlibrary.htm

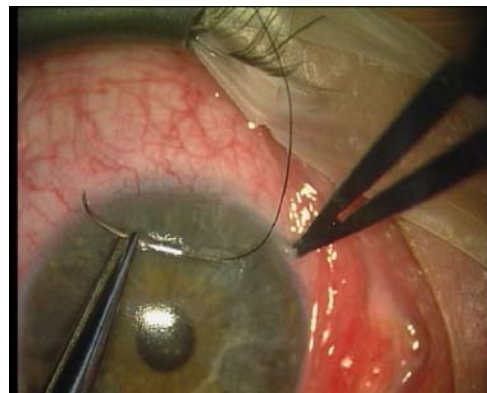
Pre- and intraoperative drops

See handout on the net www:/ucl.ac.uk/ioo/research/khawlibrary.htm

Surgical technique for trabeculectomy

1) *Position of filtration area.* Filtration surgery is most commonly performed in the superior half of the globe. This is because the upper lid protects the drainage area. A peripheral iridectomy placed at 12 o'clock is covered by the lid, and does not give rise to diplopia. Drainage blebs that are not covered by the upper lid, particularly those in the interpalpebral fissure or the lower fornix, have a high incidence of inflammation and endophthalmitis especially when antimetabolites have been used. Scleritis may also be more common, particularly with the use of antimetabolites. It is important to avoid positioning the bleb anywhere other than the superior limbus, and other procedures should be used if this is not possible.

2) *Traction suture.* Superior rectus traction sutures are still commonly used. However, the use of a corneal traction suture is becoming increasingly popular. This is because there is no chance of creating a superior rectus haematoma. Such a haematoma results in the release of growth factors that trigger wound healing. The vector force of the corneal suture is superior to that achieved with a superior rectus suture. The disadvantages of the corneal traction suture include the small risk of placing the suture too deeply and penetrating the anterior chamber (great care in buphthalmic eyes), and the chance of placing the suture too superficially with subsequent "cheese-wiring" and loss of traction. A variety of sutures can be used, but we use a 7-0 black silk suture on a semi-circular needle.



(Figure 1 Corneal traction suture)

3) *Conjunctival incision.* The conjunctiva can be incised at the limbus (fornix-based flap) or deep in the fornix (limbus-based flap). The advantages and disadvantages of either approach are summarised in table 1

The conjunctiva should be handled very gently to avoid buttonholing, particularly if antimetabolites are used. If a limbus based flap is used, the incision should be made far into the fornix. The conjunctiva and Tenon's should be entered in separate layers to minimise the chance of damaging the superior rectus muscle. An incision length of at least 10 mm is usually necessary to provide adequate exposure. For a fornix based flap an incision of about 5-10 mm is necessary. A relieving incision is used by many surgeons but is not necessary and increases the trauma and risk of wound leakage.

Table 1. Advantages and Disadvantages of fornix vs Limbus based conjunctival flap)

| | Fornix | Limbus |
|---------------------------------------|--------------------------|--------------------------|
| Length of operation | Faster than limbus based | Slower than fornix based |
| Sclerostomy exposure | Good | Reasonable |
| Large eye/small eyelid fissure | Technically easier | Difficult |

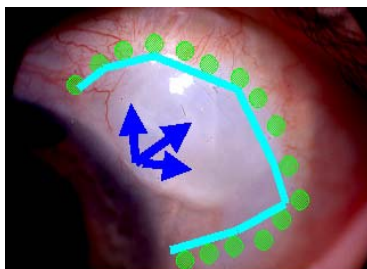
| | | |
|---|--|--|
| Area dissected/damaged | Smaller | Larger |
| Releasable suture placement through cornea | Simple | More difficult |
| Conjunctival wound leaks | Increased incidence Rare if buried corneal mattress sutures used | Less common if deep in fornix |
| Antimetabolite application | Need multiple small sponges Great care needed to insert | Fewer sponges needed Easy to insert sponge without touching wound edge |
| Post operative appearance | More diffuse (esp with MMC) | More focal (esp with MMC) |
| Reoperation | Technically easier | More difficult |

We dissect backwards with Westcott scissors to make a pocket of approximately 10-15mm posteriorly and wide for the antimetabolite sponges. When dissecting over the superior rectus tendon we lift the conjunctiva to cut attachments avoiding the tendon itself

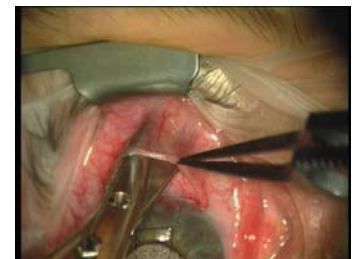

Figure 2: Dissection over rectus lifting conjunctiva)

We always previously used a limbus-based incision with antimetabolite as we were worried about postoperative leaks. However, my clinical observation of cystic blebs led me to the hypothesis that they had two things in common. The first was restricted posterior flow “the ring of



The restricted flow from the posterior incision resulting in more focal cystic blebs led us to change. The effects of treatment were very focal and the cells at the edge of the treatment area although growth arrested and can make scar tissue and encapsulate the area resulting in thinning and a cystic bleb. A fornix-based incision allowed a larger area of antimetabolite treatment, without a posteriorly placed restricting scar.

Figure 3 ring of steel and anterior aqueous flow

Similar blebs can be achieved with a limbus-based flap but the incision has to be very posteriorly placed and this result is not as consistent. This does make the subsequent scleral flap and sutures more difficult.

5) *Scleral flap* There are several types of scleral flap. The two most common types being rectangular and triangular in shape. There is no evidence that one is superior to the other. The scleral flap is usually outlined, and a lamellar dissection is carried out with a blade or scleral pocket knife. Alternatively, with a rectangular flap an incision can be made, and a scleral pocket made (like a phaco emulsification pocket) and then the two side incisions cut at the end.

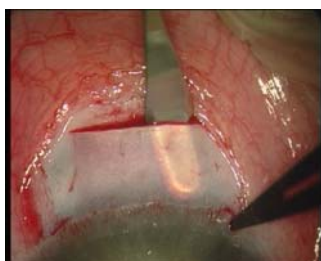

Figure 4 Scleral pocket being cut

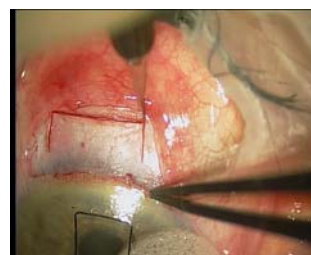

Figure 5 Limited side cuts to scleral flap to encourage posterior flow

The side incisions are not cut right to the limbus as this encourages posterior flow reducing the incidence of cystic blebs. We now cut the scleral flap before applying antimetabolite. There is also evidence that treatment under the flap increases the success rate and experimental and clinical evidence to suggest this is safe. We try to cut the largest flap possible and leave the side cuts at the limbus incomplete (1-2 mm from limbus). This forces the aqueous backwards over a wider area to get a diffuse bleb. An aqueous jet at the limbus predisposes to an anterior focal cystic bleb, whereas posteriorly directed diffuse flow of aqueous from incompletely cut sides of a large scleral flap results in a more diffuse non-cystic bleb.

The main function of the scleral flap is to provide resistance to aqueous outflow and prevent hypotony. To perform these functions the flap must be sufficiently large to cover the sclerostomy. It is important that the scleral flap is not too thin, since this increases the chance of flap dehiscence. Additional problems include formation of holes in the flap and cheese-wiring of the flap sutures. All these complications allow increased aqueous leakage and reduce flap resistance.

This is particularly important with the use of anti-metabolites, because the conjunctival resistance to outflow may not rise for several weeks or even months after surgery. This is also very important in eyes with thin, less rigid sclera such as buphthalmos and myopia. If the scleral flap does not provide adequate resistance, the eye will be hypotonous. It is important to remember that the limbus may be thinned after multiple surgery or cryotherapy. If there is a large aqueous vein running through the site of the potential scleral flap, this vein should be avoided, as when the flap is cut, the vein will end up as a perforating hole in the scleral flap. Scleral flap sutures are pre-placed at this stage whilst the eye is still firm. Scleral flap sutures are more difficult to place once the eye has been entered and is hypotonous.

4) Intraoperative antimetabolite use The full details of all antiscarring agents are too extensive for this chapter and are covered elsewhere.

The risk factors, risks of antimetabolite complications and regimen we use are summarised in **tables 4-6**. If intraoperative antimetabolites are indicated we now use them after the half thickness scleral flap has been cut but before the eye is entered, as there is reasonable pharmacokinetic and clinical data to suggest this is safe. If there is any problem with the scleral flap or scleral integrity or any sign of aqueous leak the use of antimetabolites can be withheld safely.

The variations in the technique used to deliver intraoperative antimetabolites may account for some of the variations in efficacy and complications seen in the literature, as may patients factors. It is very important for individual users to maintain a consistent technique and to build up experience with one technique.

There have been reports of 5FU given intraoperatively directly into the filtration site during surgery. However, the risk of intraocular penetration is great and commercial 5FU is alkaline with a pH of almost 9.0. Injected MMC has also been occasionally reported but one case of combined central retinal artery and vein occlusion has been reported following MMC injection. 50microlitres of MMC (one drop) irreversibly damages the cornea.

Table 4 : Risk factors for failure due to scarring after glaucoma filtration surgery

| Risk Factors | Risk 1-3+ | Comments |
|---|-----------------------|--------------------------------------|
| 1) OCULAR | | |
| Neovascular glaucoma (active) | +++ | |
| Previous failed filtration surgery | ++(+) | |
| Previous conjunctival surgery | ++ | Uncertain |
| Chronic conjunctival inflammation | ++(+) | |
| Previous cataract extraction (conj incision) | ++(+) | |
| Aphakia (intracapsular extraction) | +++ | |
| Previous intraocular surgery | ++ | Depends on type of surgery |
| Uveitis (active, persistent) | ++ | |
| A red, injected eye | ++ | |
| Previous topical medications (beta-blockers + pilocarpine) (beta-blockers+pilocarpine +adrenaline) New topical medications | + (+) +++ + (+) | Particularly if they cause a red eye |
| High preoperative intraocular pressure (higher with each 10mmHg rise) | + (+) | |
| Time since last surgery (especially if within last 30 days) | + ++(+) | |
| Inferiorly located trabeculectomy | + | |
| | | |
| 2) PATIENT | | |
| Afro-Caribbean origin May vary e.g. West vs East Africans | ++ ++(+) + | |
| Indian subcontinent origin | + | |
| Hispanic origin | (+) | |
| Japanese origin | (+) | |
| Elderly (+) vs Young + (+) (particularly children) ++ | | |

Table 5: Moorfields Eye Hospital (More Flow) intraoperative single dose anti-scarring regimen v2004 (Continuously evolving). Lower target pressures would suggest a stronger agent was required.

Low risk patients (Nothing or intraoperative 5-FU 50 mg/ml *) #

- No risk factors
- Topical medications (beta-blockers/pilocarpine)
- Afro-Caribbean (Elderly)
- Youth <40 with no other risk factors

Intermediate risk patients (Intraoperative 5-FU 50 mg/ml * or MMC 0.2mg mg/ml) #

- Topical medications (adrenaline)
- Previous cataract surgery without conjunctival incision (capsule intact)
- Several low risk factors
- Combined glaucoma filtration surgery/cataract extraction
- Previous conjunctival surgery e.g. squint surgery/detachment surgery/trabeculotomy

High risk patients (Intraoperative MMC 0.5 mg/ml) #

- Neovascular glaucoma
- Chronic persistent uveitis
- Previous failed trabeculectomy/tubes
- Chronic conjunctival inflammation
- Multiple risk factors
- Aphakic glaucoma (a tube may be more appropriate in this case)

- Intraoperative beta-radiation 1000 cGy can also be used. CAT-152 (Trabio^R) or humanised anti-TGF-beta2 antibody may be appropriate in the low and intermediate risk groups in the future based on the results of current studies. These groups account for the majority of patients undergoing glaucoma surgery.

Post operative 5-fluorouracil injections can be given in addition to the intraoperative applications of antimetabolite.

Table 6: Various intraoperative anti-scarring agents applied directly to the bleb site

| | 5-FU 50 or 25 mg/ml | beta-radiation 1000cGy | MMC 0.2-0.5 mg/ml |
|--|--|---|---|
| Delivery | 2-5 minutes | 20 secs-3 mins depending on output rate | 2-5 mins |
| Cost | UK£1.50 10ml vial | Approx UK£3000 for probe but lasts 10+ years | UK£8 2mg vial makes 5ml of 0.4 mg/ml |
| Availability | Good | Special ordering and licensing required | Good |
| Storage | Room temperature ready constituted | Lead shielded area | Powder stable at room temp Unstable once reconstituted |
| Duration effect on fibroblast proliferation | Several weeks Clinical effects several years | Several weeks | Months/permanent Cell death at higher range concentrations Growth arrest and cell death |
| Primary effect | Growth arrest | Growth arrest | |
| Control over area treated | Moderate | Precise | Moderate |

Changes in area of treatment, conjunctival and scleral flap construction, and adjustable sutures have led to a dramatic difference in terms of reducing short and long term complications. This has led to a reduction in cystic areas within the bleb from 90% to 29%. The blebitis and endophthalmitis rate over 3-5 years was 20% for older limbus based techniques with a smaller treatment area versus 0% over the same period for the current technique.⁶ Falls in complication rate have also been seen in the USA in lower risk populations from approximately 6% to 0.5% to date (Paul Palmberg personal communication) If these figures were extrapolated to an approximate figure of 50,000 trabeculectomies with antimetabolite per year in the United States it is possible that bleb related complications could be

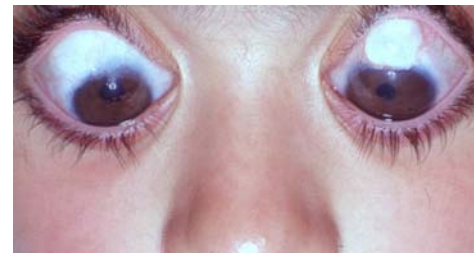
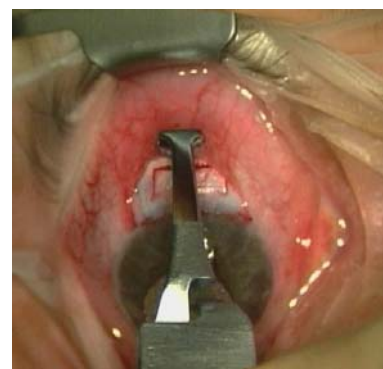
Figure 6 Showing diffuse bleb in patients right eye using large area of treatment vs a smaller area of treatment with mitomycin-c. Dramatic difference in bleb appearance.

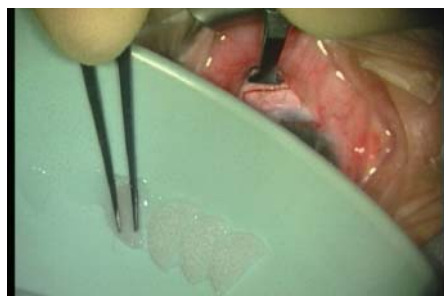5) Conjunctival clamp We use a special conjunctival T clamp designed (Duckworth-and-Kent.com No 2-686 Khaw conjunctival clamp) to hold back the conjunctiva and to prevent antimetabolite touch. This clamp maintains a pocket for antimetabolite treatment. Our experiments have shown that the antimetabolite affects mainly the area it touches, therefore protecting the edge prevents wound leaks and dehiscence.

(Figure 07 Conjunctival T clamp for holding tissue away from antimetabolite)

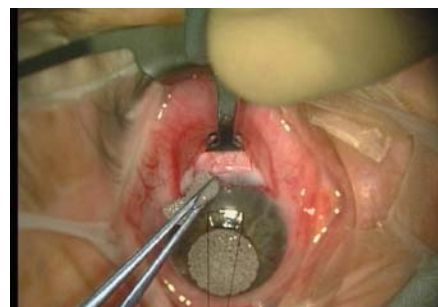

6) Type of sponge We use circular medical grade polyvinyl alcohol sponges used for LASIK corneal shields rather than other sponges. The sponges are cut in half and folded like a foldable lens **Figure 8** and they fit through the entrance to the pocket without touching the sides (approximately 5 mm X 3 and insert about 6 of these). **Figure 9**

(Figure 8 Polyvinylalcohol sponges being folded)



(Figure 9 PVA sponge being inserted avoiding the cut edge of conjunctiva)



We attempt to treat as large an area as possible, including under the scleral flap. The polyvinyl alcohol sponges maintain their integrity and do not fragment. In contrast, methycellulose sponges fragment relatively easily, with an increased chance of leaving small pieces of sponge behind in the wound. The large area of treatment results in more diffuse non-cystic blebs clinically. Increasing the surface area of treatment results in a much more diffuse non-cystic area clinically. A large area prevents the development

of a ring of scar tissue (the “ring of steel”) which restricts flow and promotes the development of a raised cystic avascular bleb

7) *Antimetabolite treatment duration and washout.* We treat for three minutes. If we need to vary the effect of MMC we vary the concentration. We use only two concentrations (0.2 and 0.5 mg/ml) For intraoperative 5FU we use 50mg/ml, washed out with 20 ml of balanced salt solution. Pharmacokinetic experiments we have done show a rapid uptake over three minutes after which there is a plateau when relatively little drug is added for extra minutes. In the period from 1 to 3 minutes there is considerable variation in the dose delivered.

6) *Paracentesis* A paracentesis should be performed to allow fine control of the anterior chamber. If the paracentesis is made obliquely, (**Figure 10**) parallel to the limbus, then the blade remains in the peripheral region of the anterior chamber with minimal chance of lens damage. Similarly, if the anterior chamber needs to be reformed in the intra- or post-operative period, a cannula introduced through an oblique paracentesis has little chance of causing lens trauma. If the entry site is placed inferiorly this can be used to gain access to the anterior chamber in the outpatient clinic if necessary. An additional advantage of a paracentesis is that it allows controlled decompression of the anterior chamber and reformation of the eye without using the sclerostomy entry site. As the scleral flap sutures are tied, the resistance of the flap to aqueous outflow can be tested by irrigating the anterior chamber with fluid through the paracentesis - enabling the opening pressure of the valve to be set with more precision. A technique that offers another level of pressure control is the use of a continuous infusion.

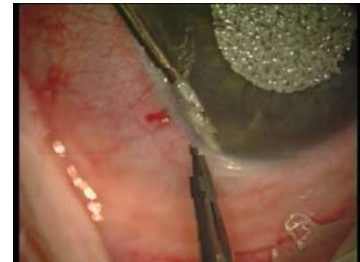

Figure 10 Oblique paracentesis minimising any risk to lens, for Lewicky infusion

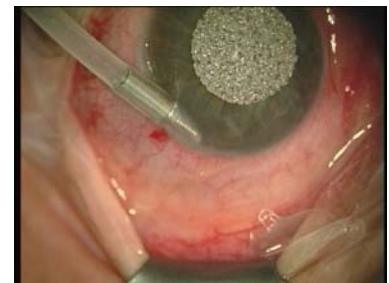

Figure 11 Anterior segment infusion to maintain intraocular pressure and gauge opening pressure of sclerostomy

7) *Infusion.* We use an anterior segment infusion (Lewicky, Visitec) on a three way tap through the paracentesis. (**Figure 11**) This maintains the pressure and rigidity of the globe throughout the surgery minimising serious complications such as intraoperative choroidal effusions particularly in high risk patients e.g. high myopes, buphthalmics. The pressure in the eye can be controlled using bottle height increasing the accuracy of the suture closure almost removing significant post operative hypotony.

8) Block removal (sclerostomy) The block removal of cornea and sclera can be achieved in a variety of ways. It can be manually cut and removed, with an appropriate blade and scissors, or a special punch instrument can be used. The sclerolimbic junction is the beginning of the blue translucent zone where the white sclera merges into clear cornea. An incision perpendicular to the surface at this point enters the anterior chamber through the anterior part of the trabecular meshwork. The incision for filtration is best done as anterior as possible as this reduces bleeding. Too posterior an incision increases the risk of the ciliary body being exposed or damaged.

If a blade and scissors are used it is difficult to cut a sclerostomy much smaller than 3 X 1.5 mm. The flap is lifted gently taking care not to cause a buttonhole. The block is outlined to at least 50% depth half without entering the anterior chamber. The eye should then be entered, the turned blade upwards and the incision opened like the action of a letter opener. If gentle traction can be applied on the flap this

keeps the blade away from the iris and underlying structures. The side incisions are then completed radially cutting backwards and the base of the flap can be cut with the blade or Vannas scissors.

A punch is the method of our choice, and a variety of these are available. There is evidence that a small sclerostomy (0.5mm) is easily adequate and may minimise astigmatism and the chance of limbal aqueous flow, and maximise the chance of controlling outflow. An anterior incision is made in a similar fashion to that previously described, slightly larger than the diameter of the punch head. The punch should then be inserted ensuring that a full thickness of limbus is engaged. The punch should then be aligned perpendicular to the eye to ensure a clean non-shelved sclerostomy. (**Figure 12**)

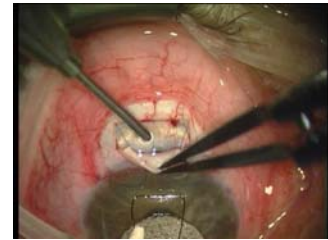


Figure 12 Small 0.5 mm titanium scleral punch to maximise flow control

8) *Peripheral iridectomy* A peripheral iridectomy is performed through the sclerostomy. The reasons for carrying out a peripheral iridectomy are to prevent iris incarceration in the sclerostomy, and in some cases to relieve any element of pupillary block. It is important that the iridectomy is not too large, otherwise the patient may experience glare and monocular diplopia. The iridectomy should be made relatively broad at the base, but short in length so a large iris defect is not created. Cutting the iridectomy with the scissors parallel to the limbus helps to achieve this. A more corneal, rather than scleral sclerostomy reduces the chance of iris incarceration and bleeding. If an infusion is used, the iris can be made to present to the wound without any intraocular manipulation, minimising trauma and the need for an assistant. (**Figure 13.**)

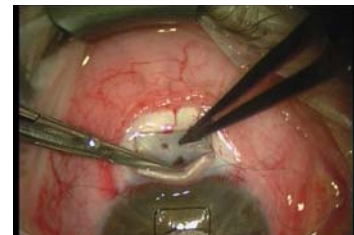

Figure 13 Iris presenting through small sclerostomy with gentle pressure on back edge when infusion used. No intraocular entry

9) *Scleral flap sutures - New adjustable, releaseable and fixed*

The function of the sutures is to secure the scleral flap and provide adequate tension so that the flap acts as an aqueous flow restrictor. The tension provided by the flap and sutures is particularly important when anti-metabolites are used as this is the primary regulator of the intraocular pressure until significant healing occurs, which may be many months if mitomycin is used. It is also important when there are particular problems with the eye e.g. an eye with angle closure whose anterior chamber is likely to be flat post-operatively, unless there is adequate aqueous outflow resistance. In these cases the sutures should be tied tight to provide sufficient resistance to prevent post-operative anterior chamber shallowing.

Several types of suture can be used, interrupted which can be lasered or cut, releaseable which can be pulled out in a variety of ways or a new type of suture which we have designed – the adjustable suture. We routinely place a suture at each posterior corner of the scleral flap, using a 10-0 nylon suture. Some sutures (e.g. 10-0 Alcon version) are better suited for use as adjustable or releasable sutures since they tend not to break when tension is applied to the suture during removal. Having placed the initial two sutures, the need for further sutures can be assessed by inflating the eye through the paracentesis and observing the amount of aqueous flow through the flap.

We have also developed a new type of adjustable suture which we have now evolved for about 3 years. These allow the tension to be adjusted post operatively through the conjunctiva with specially designed forceps with very smooth edges used for this adjustment of pressure. (DuckworthandKent.com DK adjustable suture forceps No 2-502) (**Figure 14**) The adjustable suture system allows a gradual titration of the intraocular pressure – more gradual than that seen with suture removal or massage. (**Figure**

15) We try and avoid completely cutting or removing sutures in the early post-operative phase, since this can lead to insufficient flap resistance with aqueous overdrainage and hypotony. This is a particular problem when antimetabolite therapy is used.




Figure 14 adjustable suture forceps with special fine smooth tips for transconjunctival suture adjustment without tearing conjunctiva

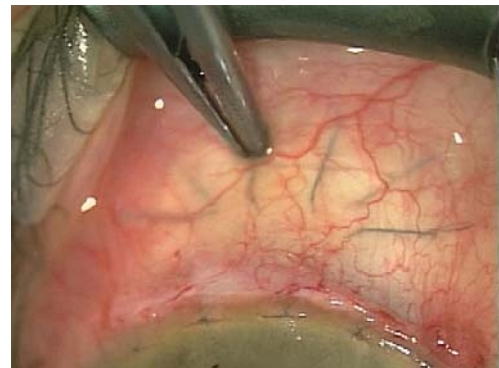

Figure 15 transconjunctival loosening of adjustable sutures without sudden fall in intraocular pressure

operative period using the technique of laser suture-lysis with a compression contact lens (e.g. Hoskins lens). There is a risk of causing a button-hole in the conjunctiva with laser suture-lysis, and this gives releasable sutures a theoretical advantage over non-releasable sutures. The use of a releasable suture technique has not been clearly shown to increase the long-term success rate of trabeculectomy, but does reduce the incidence of immediate post-operative hypotony and shallowing of the anterior chamber. Many of the sight-threatening complications of glaucoma filtration surgery are associated with hypotony. Because of the prolonged inhibition of subconjunctival scarring with antimetabolite therapy (especially with MMC), it is important to remember that hypotony can result from suture removal even several months after surgery. Late choroidal effusions and suprachoroidal haemorrhage have been reported after suture removal many months after tube drainage surgery.

10) *Conjunctival closure* The conjunctiva can be closed with a variety of sutures. For a fornix-based flap the conjunctiva can either be closed just with one or two sutures at either end of the relieving incision, or more thorough closure can be performed with interrupted mattress sutures or a continuous suture with or without corneal grooves. We make a series of corneal grooves ("Groove closure) and do all our closure sutures through these burying the knots in the cornea so there is no discomfort from the nylon sutures (Figure 16)

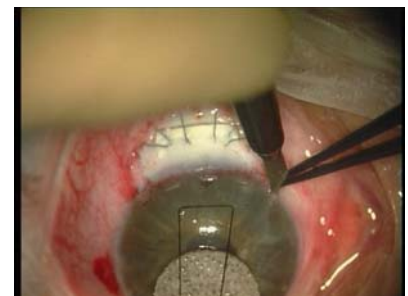

Figure 16 Corneal groove creation (5 grooves) for closure of fornix based conjunctival flap to minimise leakage and suture discomfort

(Figure 17 and 18 and 19 lateral purse string.) Suture entry via corneal groove, purse string then exit via corneal groove and tie in groove. Repeated procedure except for the conjunctival purse string for the 3 middle sutures This new technique has virtually eliminated central conjunctival retraction, leaks and suture discomfort.

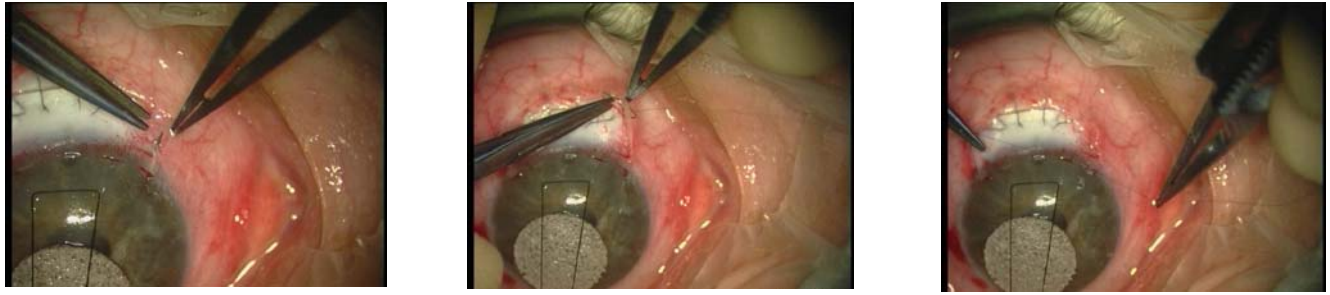


Figure 17 and 18 and 19 lateral purse string. Entry via corneal groove, purse string then exit via corneal groove and tie in groove. Repeated procedure except for the conjunctival purse string for the 3 middle sutures

For a limbus-based flap, a dissolving suture (e.g. vicryl) or nylon can be used to close conjunctiva using either interrupted or continuous suturing. We prefer a dissolving suture despite the theoretical slight increase in inflammation with vicryl because of patient comfort and ease of management. When suturing conjunctiva, it is important to be able to use a round-bodied rather than a spatulate needle if possible. This is because a spatulate needle hole tends to tear and increase in size, and cheesewire, whereas a round-bodied needle hole tends to close more spontaneously and leak less. This is particularly important if anti-metabolites, such as MMC are used. It is important to take secure bites of both Tenon's and conjunctiva if single closure is used, to ensure a watertight wound.

11) Post-operative medications. At the end of surgery a subconjunctival injection of steroid and antibiotic should be given 180 degrees away from the trabeculectomy site. Care should be taken to ensure this does not directly enter the eye through the sclerostomy. Mydriatics such as atropine are used by many ophthalmologists. Advantages include a relaxation of the ciliary muscle and pain relief, possible reduction of anterior chamber shallowing and malignant glaucoma, possible stabilisation of the blood aqueous barrier (Atropine mainly) and prevention of central posterior synechiae. Disadvantages include a dilated pupil which may increase the chance of lens-corneal touch if the anterior chamber is shallow, and loss of accommodation with blurred vision. With the use of the infusion and tight control of post operative flow we no longer use mydriatics routinely.

The use of new agents such as trabio™ (anti-transforming growth factor beta2 antibody), antiproliferative gene therapy, matrix metalloproteinase inhibitors and new anti-inflammatory agents and combinations of these will probably considerably increase the efficacy and safety of glaucoma surgery.

Download Videos and other handouts

Prevention of Intraoperative complications (glaucoma filtration surgery)
New Adjustable sutures
Post-operative antimetabolite injections with haelon GV

<http://www.ucl.ac.uk/loo/research/khawlibrary.htm>

References for clinical Surgical technique: Adjustable sutures, Antimetabolites, Safe surgery System, injections with haelon GV and commentaries on surgical technique and antiscarring agents

- Effects of intraoperative supplementation of 5-fluorouracil on filtration surgery in open angle glaucoma
Smith MF Sherwood MB Doyle JW Khaw PT **Am J Ophthalmol** 1992; 114: 737-741
(First clinical description of intraoperative 5FU)
- Single intraoperative applications of 5-fluorouracil during filtration surgery: early results 5-fluorouracil 5 minute regimen in filtration surgery Lanigan L Steurmer J Hitchings RA Khaw PT **Br J Ophthalmol** 1994;78:33-37
- Anti-fibrotic agents in glaucoma surgery
Khaw PT Wilkins MR Section 12 Chapter 31.1 – 31.7 Ophthalmology Eds Duker D Yanoff M Mosby 1998
- Preventing scarring after glaucoma filtration surgery with single application agents: a practical approach
Khaw PT Tsai JC Constable PH Cordeiro MF Occeleston NL **Asia-P J Ophthalmol** 1995; 7: 6-13
- Trabeculectomy with releasable sutures - a modified technique (The corneal buried suture technique)
Foster PJ Wilkins M Khaw PT **Asia P J Ophthalmol** 1996; 8: 13-16
- Current techniques in wound healing modulation in glaucoma surgery
Khaw PT Migdal CS **Curr Opin Ophthalmol** 1996; 7: 24-33
- Glaucoma surgery in the United Kingdom: Who, why and when
Khaw PT Siriwardena D **Eye** 1999; 13: 493-494
- “New” surgical procedures for glaucoma
Khaw PT Siriwardena D **Br J Ophthalmol** (editorial) 1999; 83: 1-2
- Glaucoma Surgery
Khaw PT Wilkins MR Shah P **Oxford Textbook of Ophthalmology** Eds: Easty D Sparrow J. Oxford Univ 1999
- Antifibrosis agents in primary trabeculectomy
Khaw P T **American Academy of Ophthalmology** Glaucoma 1999: Concepts and controversies. p135-140
- Wound Healing - laboratory investigation and modulating agents
Occeleston N L Daniels J Khaw P T **An introduction to vascular biology** Eds Hunt B Poston L Halliday A Schachter M Cambridge University Press 2000 ISBN 0521623308
- Effects of sponge type, size and application technique on tissue levels of 5-fluorouracil
Wilkins M Occeleston N Waters L Kotecha A Khaw PT **Br J Ophthalmol** 2000; 84: 92-97
- Anterior chamber flare after trabeculectomy or phacoemulsification
Siriwardena D Kotecha A Minassian D Dart JKG Khaw PT **Br J Ophthalmol** 2000; 84:1056-1057
- Risk factors for the development of post trabeculectomy endophthalmitis
Lehmann OJ Bunce C Matheson MM Maurino V Khaw PT Wormald RPL Barton K **Br J Ophthalmol** 2000;84:1349-1353
- Modulation of wound healing after glaucoma surgery (MRC GDFB Wellcome MFC LC TW) RNIB)
Khaw PT Chang L Wong T Mead A Daniels JT Cordeiro MF **Curr Opin Ophthalmol** 2001;12: 143-148
- Wound healing modulation in glaucoma surgery Khaw PT Papadopoulos MP **Glaucoma perspectives in practice** 2001; 3.2; 1-4
- Improving Glaucoma Filtration Surgery (MRC) Papadopoulos M Khaw PT **Eye** 2001;15:131-132
- Trabeculectomy in the UK: is there room for improvement? Khaw PT Well AP **Eye** 2001; 15: 437-438
- Modulating wound healing in glaucoma surgery: First Hong Leong Professorial Lecture 2002
Khaw PT Papadopoulos **Asia Pacific J Ophthalmol** 2001; 13: 9-16
- A randomised, masked, prospective trial of intraoperative 5-fluorouracil in an East African population
Yorston D Khaw PT **Br J Ophthalmol** 2001; 85: 1028-1030
- Advances in Glaucoma Surgery – Evolution of antimetabolite adjunctive therapy and surgical techniques (and Adjustable sutures)
Khaw PT **J Glaucoma** 2001; 10: S81-S84
- A preliminary prospective randomised double masked placebo controlled trial of a novel human anti TGF-beta2 monoclonal antibody in trabeculectomy
Siriwardena D Khaw PT King AJ Donaldson ML Overton BM Migdal C Cordeiro MF **Ophthalmology** 2002; 109:427-431
- Modulating scarring and new surgical techniques in glaucoma surgery
Khaw PT Chang LP **Ophthalmology** Eds: Duker D Yanoff M Mosby 2003 chap 241 pg 1596-1603

Optimum method of applying antimetabolites (Adjustable sutures)
 P T Khaw **Trials and tribulations in glaucoma** AAO publications 2003 p155-159 (All)
 Controlling tissue repair and regeneration after surgery: new treatments and techniques
 Khaw PT Clarke JCK Mead AL Wong TTL Cambrey AL Daniels JT
Basel Glaucoma Symposium Ed Sharaawy T Flammer J Ciba Vision 2003
 The Safe Surgery System for glaucoma Khaw PT in **Key Questions in glaucoma** Ed Susanna R 2004
 Antimetabolites and antiscarring agents
 Khaw PT Trope GE **Glaucoma Surgery: Indications Techniques and Complications** 2004
 Trabeculectomy - the Moorfields Safe Surgery System (Adjustable sutures)
 Khaw PT Shah P in **Textbook of Glaucoma Surgery** Eds: Mermoud and Sharaawy Dunitz 2004
 Primary Open Angle Glaucoma
 Weinreb RN Khaw PT **Lancet** 2004; 363: 1711-1720
 Modulation of healing after glaucoma surgery
 Khaw PT Jones E Hussein R Clarke R Mireskandari K **Glaucoma Today** 2004; July/ August; 12-19
 Trabeculectomy in East Asians - a review
 Hussain R Clarke J Seah SK Khaw PT **Eye** 2004 ^{epub}
 Flap and suture manipulation after trabeculectomy with adjustable sutures: titration of flow and intraocular pressure in guarded filtration surgery Wells AP Bunce C Khaw PT **J Glaucoma** 2004

Basic research underpinning development of clinical techniques and new treatments for scarring

The effects of beta-radiation on proliferating human Tenon's capsule fibroblasts
 Khaw PT Ward S Grierson I Rice NSC **Br J Ophthalmol** 1991; 75: 580-583
 5-Fluorouracil and beyond Khaw PT Grierson I Hitchings RA Rice NSC **Br J Ophthalmol** 1991; 75: 577-588.
 Long term effects of sodium butyrate and 5-fluorouracil on ocular fibroblast proliferation
 Khaw PT Ward S Porter A Grierson I Rice NSC **Invest Ophthalmol Vis Sci** 1992; 33: 2043-2052
 Tissue effects of Intraoperative vs Post Operative Treatments with antiproliferative agents
 Khaw PT Sherwood MB Doyle JW Smith MF Grierson I McGorray S Schultz G **Int Ophthalmol** 1992; 16: 381-385
 Five-minute treatments with fluorouracil, floxuridine, and mitomycin have long-term effects on human Tenon's capsule fibroblasts. Khaw PT; Sherwood MB; MacKay SL; Rossi MJ; Schultz G **Arch Ophthalmol** 1992, 110(8) p1150-4
(First description of long term effects of 5 minute applications including 5-FU - basis of 5-FU regimen)
 Prolonged localised tissue effects from a 5-minute exposure to fluorouracil and mitomycin-c Khaw PT Doyle JW Sherwood MB Grierson I Schultz G McGorray S **Arch Ophthalmol** 1993: 111; 263-267
 Effects of intraoperative 5-fluorouracil or mitomycin C on glaucoma filtration surgery in the rabbit
 Khaw PT Doyle JW Sherwood MB Smith MF McGorray S **Ophthalmology** 1993: 100; 367-372
 Dangers of direct injections of antiproliferatives into blebs
 Khaw PT Sherwood MB Hitchings RA Hitchings RA Miller MH Rice NSC **Eye** 1993; 7: 481-482
 Targetted, focal, titratable, long term inhibition of ocular fibroblast proliferation and post surgical scarring using single five minute exposures to antiproliferative agents
 Khaw PT Ocleston N L Schultz GS Sherwood MB Grierson I **Wound Rep Regeneration** 1993; 1: 110
 Effects of different regimens of 5-fluorouracil on experimental filtration surgery
 Doyle JW Sherwood MB Smith MF McGorray S Khaw PT **Invest Ophthalmol Vis Sci** 1993; 34: 3313-19
 Activation and suppression of fibroblast function Khaw PT Ocleston NL Schultz GS Grierson I **Eye** 1994;8:188-195
 Effects of single exposures to antiproliferative agents on ocular fibroblast mediated collagen contraction
 Ocleston NL Alexander RA Mazure A Larkin G Khaw PT **Invest Ophthalmol Vis Sci** 1994;35:3681-3690
 Anti-proliferative agents for the prevention of scarring after surgery: friend or foe? Khaw PT **Br J Ophthalmol** 1995; 79: 627
 Antimetabolites and glaucoma filtration surgery Khaw PT **Curr Med Lit** 1996; 6 (2): 69- 75
 Controlling scarring after glaucoma surgery in developing countries
 Khaw PT Wilkins MR Foster PJ Seah S **Comm Eye Health** 1996; 9: 42-47
 T-lymphocyte/fibroblast interactions and wound healing
 Crowston JG Salmon M Khaw PT Akbar AN **Trans Bioch Soc** 1997; 25: 529-531
 Antimetabolites Wilkins M Crowston JF Cordiero MF Khaw PT **Semin Ophthalmol** 1997: 12; 143-151
 Antimetabolites for all? (Editorial) Khaw PT **Eye** 1997; 11: 764-765
 The effect of surface area of MMC treatment on an experimental model of filtration surgery
 Cordeiro MF Constable PH Alexander RA Khaw PT **Invest Ophthalmol Vis Sci** 1997; 38: 1639-46
 Single exposures to antiproliferatives - long term effects on ocular fibroblast wound-healing behaviour
 Ocleston NL Daniels JT Tarnuzzer RW Sethi KK Alexander RA Bhattacharya S Schultz G Khaw PT **Invest Ophthalmol Vis Sci** 1997; 38: 1998-2007
 Antimetabolite induced apoptosis in Tenon's capsule fibroblasts
 Crowston JG Akbar AN Constable PH Ocleston NL Daniels JT Khaw PT **Invest Ophthalmol Vis Sci** 1998; 39: 449-454

Long term growth arrest of human Tenon's fibroblasts following single applications of beta radiation
 Constable PH Crowston JG Occeleston NL Cordeiro MF Khaw PT **Br J Ophthalmol** 1998; 8: 174 - 180

Understanding and controlling the scarring response: the contribution of histology and microscopy
 Daniels JT Occeleston NL Crowston JG Cordiero MF Alexander RA Wilkins MJ Porter R Brown RA Khaw PT **Microscopy Res Tech** 1998; 42: 317 - 333

Ultrastructural changes during contraction of collagen lattices by ocular fibroblasts
 Porter R Brown RA Eastwood M Occeleston NL Khaw PT **Wound Rep Regeneration** 1998; 6: 157-166

Effects of antimetabolite induced cellular growth arrest on fibroblast/fibroblast interactions
 Daniels JT Occeleston NL Crowston JG Khaw PT **Exp Eye Res** 1999; 69: 117-127

Transforming Growth Factor beta 1, beta 2, and beta 3 *in vivo*: Effects on normal and mitomycin-c modulated conjunctival scarring
 Cordeiro MF Reichel M Gay J D'Esposito Alexander RA Khaw PT **Invest Ophthalmol Vis Sci** 1999; 40: 1875-1982

Human anti-transforming growth factor beta antibody: a new glaucoma anti-scarring agent
 Cordeiro MF Gay J Khaw PT **Invest Ophthalmol Vis Sci** 1999; 10: 2225-2234

Cell and protein adhesion studies in glaucoma drainage device development
 Lim S Faragher RG Wong L Lloyd AW Denyer SP Willis S Khaw PT Allan BDS **Br J Ophthalmol** 1999; 83: 1168-1171

Molecular therapy in ocular wound healing
 Cordiero MF Ali RR Schultz GS Bhattacharya SS Khaw PT **Br J Ophthalmol** 1999; 83: 1219-1223

Matrix metalloproteinases in sterile corneal melts
 Geerling G Jousen AM Daniels JT Mulholland B Khaw PT Dart JKG **Proc N Y Acad Sci** 1999; 878: 571-574

Choroidal effusions and hypotony caused by severe anterior lens capsule contraction after cataract surgery
 Salzmann J Khaw PT Laidlaw A **Am J Ophthalmol** 2000; 129: 253-254

Risk factors for proliferative vitreoretinopathy after primary vitrectomy- a prospective study
 Kon CH Occeleston NL Khaw PT Aylward GW **Br J Ophthalmology** 2000; 84: 506-511

The effects of TGF beta 1 2 and 3 on Tenons capsule fibroblast proliferation migration and contraction.
 Cordeiro MF Khaw PT **Invest Ophthalmol Vis Sci** 2000; 41:756-763

The role of the immune system in conjunctival wound healing after glaucoma filtration surgery
 Chang L Crowston JF Cordeiro MF Akbar AN Khaw PT **Surv Ophthalmol** 2000; 45: 49-68

Matrix metalloproteinases and their natural inhibitors in retinal membranes of proliferative diabetic retinopathy (PDR)
 Salzmann J Limb GA Khaw PT Gregor ZJ Webster L Chignell AH Charteris DG **Br J Ophthalmol** 2000; 84: 1091-1096

Temporal stimulation of corneal fibroblast wound healing activity by differentiating epithelium *in vivo*
 Daniels J Khaw PT **Invest Ophthalmol Vis Sci** 2000; 41: 3754-3762

Molecular responses of human dermal fibroblasts to dual cues: contact guidance and mechanical load
 Mudera V Pleass R Eastwood M Tarnuzzer R Schultz GS Khaw PT Brown RA **Cell Motility and Cytoskeleton** 2000; 45: 1-9

Phenotypic differences in extracellular matrix reorganisational ability and MMP-2 activity between oral mucosal and skin fibroblasts *in vitro* are associated with the differential expression and production of TIMP-2
 Stephens P Davies KJ Occeleston NL Pleass R Kon C Daniels J Khaw PT Thomas DW **Br J Dermatol** 2001; 144: 229-237

Normal and Growth-arrested human Tenon's fibroblasts produce interferon-beta which prevents T-cell apoptosis
 Chang L Crowston JG Sabin CA Khaw PT Akbar AN **Invest Ophthalmol Vis Sci** 2001; 42:1531-1538

Adjuvant therapy with 5-fluorouracil and low molecular weight heparin prevents post operative proliferative retinopathy: results from a randomised controlled clinical trial (GD MRC Sutor)
 Asaria RHY Kon CH Bunce K Charteris D Wong D Khaw PT Aylward GW **Ophthalmology** 2001; 108; 1179-1183

How to predict proliferative vitreoretinopathy - a prospective study (GD MRC Sutor)
 Asaria RHY Kon CH Bunce K Charteris D Luthert PJ Khaw PT Aylward GW **Ophthalmology** 2001; 108;1184-1186

Experimental filtration surgery with amniotic membrane transplantation
 Barton K Budenz DL Khaw PT Tseng SCG **Invest Ophthalmol Vi Sci** 2001; 42: 1762-1768

Experimental flow studies in glaucoma filtration implant development
 Lim S Allan BDS Khaw PT Willis S AW Lloyd A Muir P Gard RGA Faragher Olliff CJ Hanlon GW Wong L Reed S Denyer SP **Br J Ophthalmol** 2001; 85: 1231 - 1236

Matrix metalloproteinases: A role in the contraction of vitreoretinal scar tissue (GDFB)
 Sheridan CL Occeleston NL Hiscott P Kon CH Khaw PT Grierson I **Am J Path** 2001; 159: 1555-1566

Apoptosis gene expression and death receptor signalling in mitomycin-c treated Tenon's fibroblasts
 Crowston JG Constable PH Daniels JT Chang L Akbar AN Khaw PT **Invest Ophthalmol Vis Sci** 2002 ; 43 : 692-699 (Wellcome 045202 RNIB)

Surgery for glaucoma surgery in the 21st century: how close are we to an utopian world? (MRC Dti link IGA)
 Khaw PT Wells AP Lim KS **Br J Ophthalmol** 2002; 86:1-2

Production of Interferon-beta by Human Tenon's Fibroblasts; a Possible Mediator for the Development of Chronic Conjunctival Inflammation (Wellcome MRC g9330070)
 Chang L Siriwardena D Crowston JG Akbar AN Khaw PT **Br J Ophthalmol** 2002; 86:611-615

Gene therapy: new "magic bullets" to prevent ocular scarring (GDFB Wellcome RNIB MRC)
 Khaw PT Cambrey AD Limb GA Daniels JT **Br J Ophthalmol** 2002; 86:490-492

The Moorfields/Medical Research council study of intraoperative 5-FU in glaucoma filtration surgery

Khaw PT and the More Flow surgery study group **Clin Exp Ophthalmol** 2002; 30: a45 (MRC)
 Matrix metalloproteinases in disease and repair processes in the anterior segment
 Wong TTL Sethi C Daniel JT Limb A Murphy G Khaw PT **Surv Ophthalmology** 2002; 47: 239-256
 Expression of MMP-2 and MMP-9 by retinal Muller Cells: Modulation by extracellular bound TNF- α
 Limb GA Daniels JT Pleass R Charteris DG Luthert PJ Khaw PT **Am J Path** 2002; 160: 1847-55
 In vivo production of interferon beta by human Tenon's fibroblasts; a possible mediator for the development of chronic conjunctival inflammation.
 Chang L Siriwardena D Wilkins MR Crowston JG Akbar AN Khaw PT **Br J Ophthalmol** 2002; 86:611-5
 Novel antisense oligonucleotides targeting TGF-beta inhibit in vivo scarring and improve surgical outcome
 Cordeiro MF Mead AM Ali RR Alexander RA Murphy S Chen C York-Defalco C Dean NM Schultz GS Khaw PT
Gene Therapy 2003; 10: 59-71
 Matrix metalloproteinase inhibition modulates fibroblast-mediated contraction and collagen production in vitro
 Daniels JT Cambrey A Ocleston N L Garrett Q Tarnuzzer R Schultz GS Khaw PT **Invest Ophthalmol Vis Sci** 2003 ;
 44 :1104-1110 (Eranda Hayman Guide dogs Wellcome)
 Matrix metalloproteinase inhibition significantly reduces post operative scarring following experimental glaucoma filtration
 surgery (Wellcome) Wong TTL Mead AL Murphy G Khaw PT **Invest Ophthalmol Vis Sci** 2003 ; 44 :1098-1103
 Role of transforming growth factor beta in conjunctival scarring
 Cordeiro MF Alexander RA Reichel MB Gay JA Khaw PT **Clinical Science** 2003; 105: 181-187
 Beta radiation – new uses for an old modality: a review (Wellcome 056045, Frost MRC g9330070)
 Kirwan JS Constable PH Murdoch I Khaw PT **Eye** 2003; 17: 207-215
 Optimal glaucoma surgery (letter) Khaw PT Wells AP Lim KS **Br J Ophthalmol** 2003;
 Anti-Transforming Growth Factor- β 2 antibody: a new post operative anti-scarring agent in glaucoma surgery
 Mead AL Wong TTL Cordiero MF Anderson IK Khaw PT **Invest Ophthalmol Vis Sci** 2003; 44: 3394-3401 (CAT)
 Temporal and spatial expression of matrix metalloproteinases during wound healing of human corneal tissue
 Daniels JT Geerling G Alexander RA Murphy GM Khaw PT Saarialho-Kere U **Exp Eye Research** 2003; 77: 653-664 (RNIB
 Wellcome Trust travel, ERANDA, Hayman, Academy finland, Sigrid Jesulius foundation, Helsinki Univ Central Hospital
 Research Funds, Deutsch Forschungmeinschaft
 Reduction in cystic bleb complications after Mitomycin-c trabeculectomy using fornix versus limbus based incisions
 Well AP Cordeiro MF Bunce C Khaw PT **Ophthalmology** 2003; 110: 2192-2197
 CTGF mediates TGFbeta1 stimulated collagen matrix contraction by fibroblasts
 Daniels JT Schultz GS Blalock TD Garrett Q Grotendorst GR Dean NM Khaw PT **Am J Path** 2003; 163: 2043-2052
 The problem of dural scaring: a solution using 5-fluorouracil (MRC Wellcome)(M no JN 00169-2003.R1)
 Spinks RL Baker SN Jackson A Khaw PT Lemon RN **J Neurophysiology** 2003; 90: 1324-1332
 Connective Tissue Growth Factor is involved TGF- β 1 stimulation of Myofibroblast Differentiation and Collagen Matrix
 Contraction In the Presence of Mechanical Stress
 Garrett Q Khaw PT Blalock TD Schultz GS Grotendorst GS Daniels JT **Invest Ophthalmol Vis Sci** 2004: 45; 1109-1116
 The International Glaucoma Association Kruschner Lecture: Recent advances in the treatment of glaucoma – the role of research
 Khaw PT **Glaucoma Forum** 2004; 41:14-22
 MMP production by lens epithelial cells is involved in cell migration and lens capsule contraction: a role in posterior capsule
 opacification (Wellcome Wong RNIB Daniels MRC 9330070 Hayman Trust)
 Wong TTL Daniels JT Crowston JG Khaw PT **Br J Ophthalmol** 2004; 88: 868-872
 National Survey of antimetabolite use in glaucoma surgery in the United Kingdom
 Siriwardena D Edmunds B Wormald RPL Khaw PT **Br J Ophthalmol** 2004; 88: 873-876
 Needle revision of failing and failed trabeculectomy blebs with adjunctive 5-fluorouracil: long term survival analysis Broadway
 DC Bloom PA Bunce CV Thiagarajan M Khaw PT **Ophthalmology** 2004; 111:665-673 (MRC IGA MEH Trustees)
 The effects of single doses of beta radiation on ocular fibroblast wound healing behaviour
 Constable PH Ocleston NL Crowston JF Daniels J Khaw PT **Br J Ophthalmol** 2004 88 169-73 (GDB Wellcome IGA Frost)
 T-lymphocyte mediated lysis of mitomycin-c treated Tenons capsule fibroblasts
 Crowston JG Chang LH Daniels JT Khaw PT Akbar AN **Br J Ophthalmol** 2004 , 88 399-405
 Control of excessive scar formation in the eye with dendrimer based constructs of glucosamine
 Shaunak S Thomas S Gianasi E Godwin A Jones E Duncan R Mireskandari K Luthert P Patterson S
 Khaw PT Brocchini S **Nature Biotechnology** 2004; 22: 977-984 (NIH Moorfields Trustees Katz AlconAward)

Acknowledgements

Our research has been supported in part by the Medical Research Council (G9330070), the Guide Dogs for the Blind, the Wellcome Trust, Moorfields Trustees and the Michael and Ilse Katz foundation. This chapter is dedicated to the memory of Ilse Katz who inspired us and helped us to help others.